

TREATMENT OF MIDLINE DIASTEMA – MULTIDISCIPLINARY MANAGEMENT: A CASE REPORT

Dr. Haroon Shahid Qazi^a, Dr. Khurram Ataullah^b

^a BDS,MS. Associate Professor. Head of Orthodontic Department, Margalla College of Dentistry. Rawalpindi-Pakistan. Program Director, Dental Centre - Centre for Continuing Dental Education (CCDE) Islamabad, Pakistan.

^bBDS, MDS, MRD RCS. Assistant Professor Head of Periodontology. Fatima Memorial College, Lahore-Pakistan.

Abstract

Introduction: Midline diastema is a common cosmetic problem. Based on the etiology, it can be physiological, pathological or iatrogenic. Various innovative therapies including restorative, orthodontic and surgical procedures are available for the treatment of midline diastema.

Case History: A young female patient reported with a midline diastema, that was associated with a crestal frenal attachment and skeletal and dental class I relationship.

Progress: Midline diastema and spaces were closed by orthodontic treatment. Teeth were moved anteriorly maintaining class I dental relationship. At the finishing stage, six weeks before appliance removal frenectomy was performed and wrap around upper and lower retainers were used.

Conclusion: Midline diastema and crestal frenal attachment are two different problems. Therefore both problems should be diagnosed accurately and treated for better long term results. Thus a working relationship and team work of an Orthodontist and a Periodontist is mandatory.

Keywords: Spacing, crestal frenal attachment, frenectomy.

Correspondence: Program Director, Centre for Continuing Dental Education (CCDE) 164 I/10-2 Islamabad, Pakistan Phone Number: 0300-5001774.

INTRODUCTION

Spacing greater than 0.5mm between the proximal surfaces of adjacent teeth is described as a “diastema” and if it is in the anterior maxilla in the midline it is known as a “midline diastema”¹, which is a common aesthetic complaint of patients, seeking orthodontic treatment.

Midline diastema's can be physiological, dentoalveolar, due to a missing tooth, due to peg shaped lateral, midline supernumerary teeth, proclination of the upper labial segment, prominent frenum and due to a self inflicted pathology by tongue piercing^{2,3}.

Midline diastema may be considered normal for many children during the eruption of the permanent maxillary incisors, at the ugly duckling stage. However if the midline diastema is present after eruption of permanent

canines or is more than 2-4mm than there is always an underlying cause.

Angle and Sicher stated that an abnormal frenum is a cause of midline diastema^{4,5}, while Tait in his study reported that frenum is an effect and not a cause for the incidence of diastema⁶.

The following case report describes the management of patient with midline diastema.

Case History

A female patient, 19 years of age reported to the Department of Orthodontics, Dental Centre, Islamabad, with the chief complaint of a large gap between the upper front teeth. Medical history revealed no systemic disease or allergies. Patient was a skeletal class I, had a symmetrical face with an average facial height and a straight profile. Intraoral examination showed a molar and canine class I relationship on both sides, with generalized spacing in both maxillary and mandibular teeth, more in the anterior region. A large midline diastema measuring 6mm was present between the maxillary central incisors and a crestal frenal attachment (Fig.1).

A simple clinical diagnostic test (blanching test) was performed for an abnormal crestal frenum by observing the location and its attachment when pressure was exerted on the frenum by stretching the upper lip upwards. Blanching of the papilla occurred which clearly gave an indication of a heavy fanlike band of tissue attached to the palatine papilla. This clinical diagnosis was confirmed by a simple periapical radiograph which showed a spade shaped interdental bone (Fig.6).

Treatment Plan and Progress

The treatment objective was to treat the patient with fixed orthodontic appliance and to close all spaces towards the anterior, maintaining class I canine and molar relationships, normal overjet and overbite. After the finishing stage before removal of the fixed appliances a frenectomy was planned with long term retention.

To meet these objectives the treatment was started by banding and bonding the upper and the lower arches, using 0.016"x 0.022" slot, Roth prescription, straight wire bracket system. Initial leveling and alignment was achieved in the first 4 months. Mid treatment involved in space closures towards the anterior using push coil NiTi springs. Upper and lower molars were pulled anteriorly on a 0.016"x 0.022" stainless steel wire with closing loops. The case was finished on 0.019"x 0.025" stainless steel wire (Fig.2).

At this stage frenectomy was carried out under local anesthesia. The crestal attachment was severed, and the frenum was secured apically by placing suture that engaged the periosteum. Primary closure was achieved with 4/0 black silk interrupted stitches. The patient was advised to follow Charter's technique for plaque control and mouth rinsing with chlorhexidine gluconate 0.2% was advised. Acetaminophen 1000 mg in thrice daily dose was prescribed for 3 days. The healing was uneventful and stitches were removed after 10 days.

Fixed appliances were removed (Fig.4) six weeks after suture removal, and a wrap around retainer was given for both arches. Patient was advised to wear the retainer 24 hours for the first year after removal and then only night time wear. Results are perfectly maintained three years after treatment was finished (Fig. 5). The patient has been advised for another two years of night time retainer wear. Interdental bone height was increased and interdental bone shape changed from spade shaped to a more wedge like shape (Fig.6,7,8).

Discussion

A midline diastema at some stage of development is normal. However if it persists after the eruption of permanent canines and in adult hood then it is an abnormal feature of normal occlusion, a cause of concern for the patient, and if the diastema is large it may be a cause of speech problems. There has to be an underlying cause. The diastema is treated only after an accurate diagnosis is made and the cause determined. Some etiological factors like supernumerary teeth, habits or a cyst must be removed before orthodontic treatment but other factors like a high frenum has to be treated after orthodontic closure of diastema has been achieved. There have been reports of frenectomies before or without orthodontic treatment as well⁷.

A lot of different treatment modalities have been reported for treating a midline diastema's, which include composite restorations⁸, ceramic veneers⁹, micro-magnets and different orthodontic biomechanics^{10,11}. Here we treated the diastema by fixed orthodontics, followed by frenectomy to prevent relapse. Generally abnormal frenal attachment may require removal either before orthodontic treatment or at the end of active treatment. The advantage of excision prior to orthodontic treatment is the ease of surgical access. If the surgery is performed before the orthodontic procedure, the scar tissue might impede the closure of diastema but the noted advantages of excision after orthodontic tooth movement is the scar tissue formation which helps maintain closure of diastema. Periodontal pressure has always been considered to be a cause of orthodontic relapse and in

case where a crestal frenal attachment has been diagnosed, it is mandatory to treat the problem with a frenectomy procedure for the following reasons ¹²:

1. To avoid relapse.
2. for cosmetic reasons.
3. To maintain good oral hygiene.
4. To decrease the risk of periodontal destruction due

- to fibers extending to the gingival margins.
5. To increase interdental bone height.
6. To modify interdental bone shape.

Accurate and correct diagnosis is necessary and timely correction of the problem is mandatory, for esthetics, better occlusion and future periodontal health.

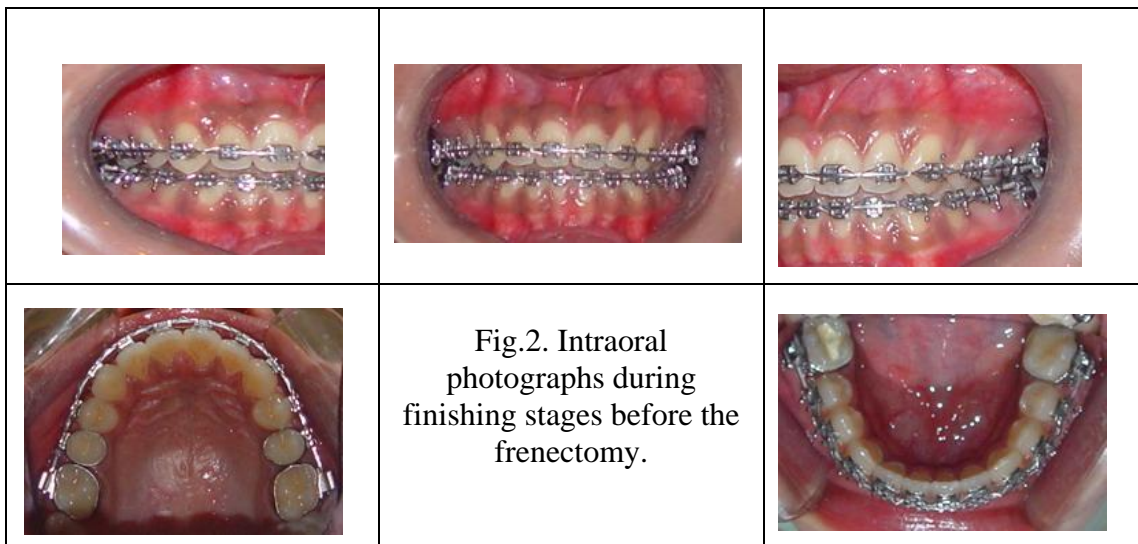
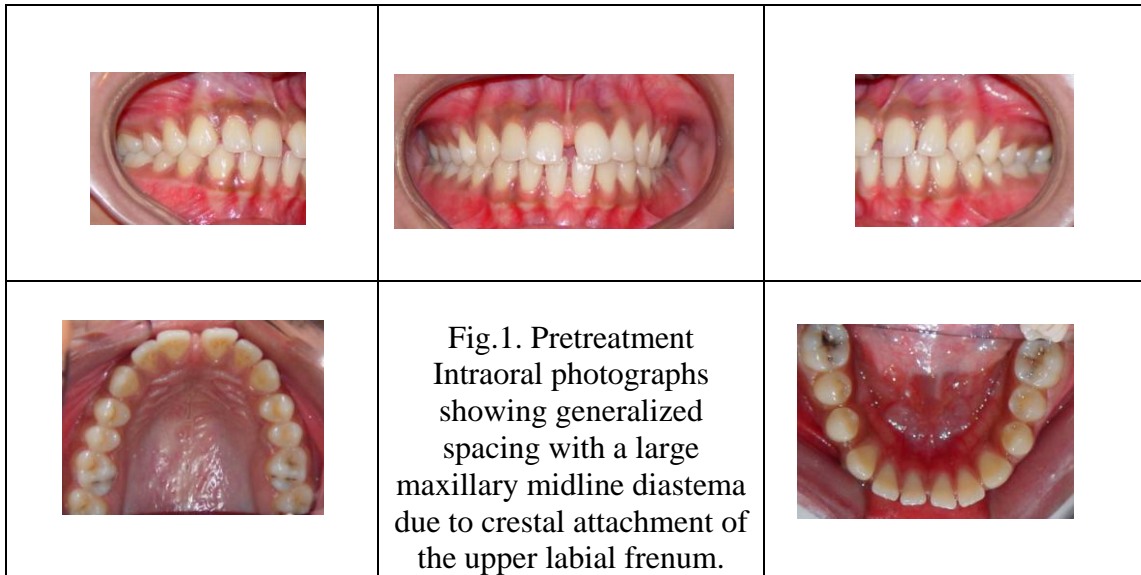
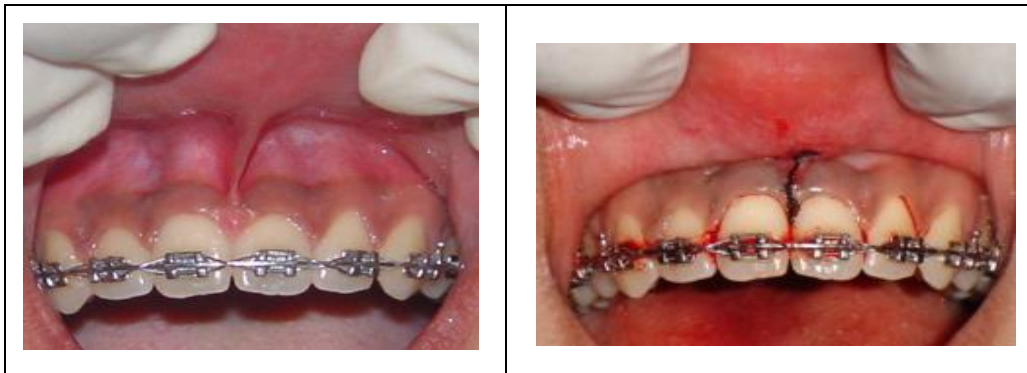



Fig.3. Intraoral photographs before and after frenectomy.

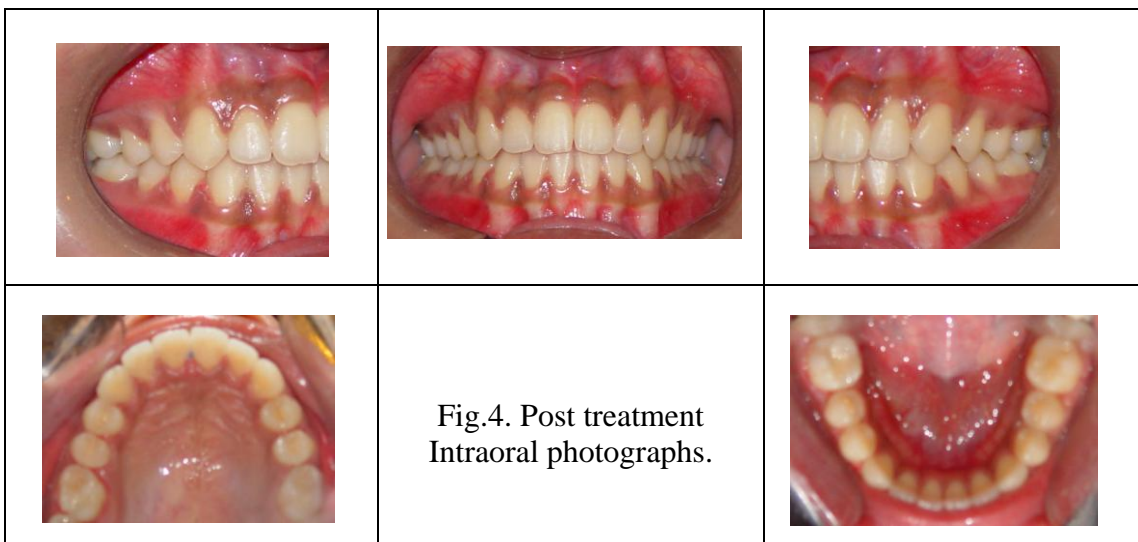

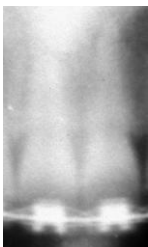
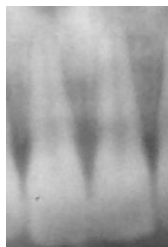


Fig.4. Post treatment Intraoral photographs.

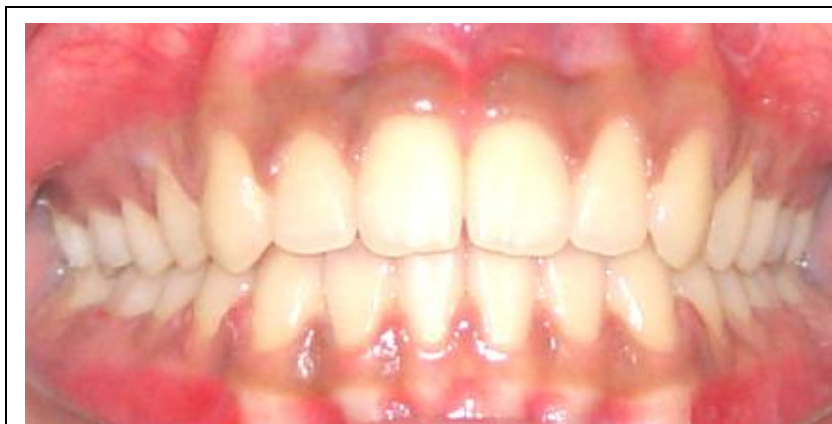

Fig.5. Intraoral frontal view three years after treatment.

		
<p>Fig.6. Pretreatment periapical radiograph showing spade shape interdental bone.</p>	<p>Fig.7. Periapical radiograph before frenectomy.</p>	<p>Fig.8. Periapical radiograph three years after treatment, showing a wedge shape interdental bone.</p>

Conclusion

There has been a big debate whether midline diastema is a cause of high frenal attachment or high frenal attachment is a cause of midline diastema. Without falling into this controversy we consider a midline diastema unsightly. It must be noted that a midline diastema is one problem and crestal frenal attachment is another problem of its own nature, therefore both problems should be considered and corrected. Patients normally would just come up with a concern of a gap between their central incisors. Hardly any patient complains of a high frenal attachment. Therefore it is important for the consultant to work as a team to address, discuss and treat the periodontal concern as well. Out of all the different treatment modalities available to treat midline diastema's, we suggest that midline diastema correction with orthodontic treatment followed by frenectomy is a better option in young individuals. Although it is a longer treatment option but it gives a more natural and better long term results.

References

1. Keene HJ. Distribution of diastemas in the dentition of man. *Am J Phys Anthropol* 1963;21:437-41.
2. Edwards JG. The diastema, the frenum, the frenectomy a clinical study. *Am J Orthod* 1977; 71: 489-508.
3. Rahilly G, Crocker C. Pathological migration: an unusual cause of midline diastema. *Dent Update* 2003; 30(10): 547-9.
4. Angle EH. Treatment of malocclusion of the teeth. 7th ed. S.S. White Dental Manufacturing Co: Philadelphia; 1907. p. 103-4.
5. Sicher H. Oral anatomy. 2nd ed. The C.V. Mosby Co: St. Louis; 1952. p. 185,272-3.
6. Tait CH. The median frenum of the upper lip and its influence on the spacing of the upper central incisor teeth. *Dent Cosmos* 1934;76:991-2.
7. Koora K, Muthu MS, Rathna PV. Spontaneous closure of midline diastema following frenectomy. *J Indian Soc Pedod Prev Dent* 2007;25:23-6.
8. Gleghorn T. Direct composite technique for a smile makeover. *Dent Today* 1997;16:40,42,44.
9. Kinderknecht KE, Kupp LI. Aesthetic solution for large maxillary anterior diastemas and frenum attachment. *Pract Periodontics Aesthet Dent* 1996;8:95-102.
10. Springate SD, Sandler PJ. Micro-magnetic retainers: An attractive solution to fixed retention. *Br J Orthod* 1991;18:139-41.
11. Follin ME. Orthodontic movement of maxillary incisor into the midline: A case report. *Swed Dent J* 1985;9:9-13.
12. Newman, Takei, Caranza. Clinical periodontology. 9th ed. WB Saunders Co: 2003.