

# Assessment of smile characteristics on frontal smiling photograph compared to selfie view. A Pilot study

Amnah Munir<sup>a</sup>, Haroon Shahid Qazi<sup>b</sup>, Kausar Khan<sup>c</sup>, Kiran Raja<sup>d</sup>

**Introduction:** Photography has become an indispensable tool in Orthodontic treatment planning and in assessment of treatment outcome. Patients have become more aware and demanding of achieving excellent smile aesthetics. Use of selfie photographs has become a common practice in young adults. The aim of this study was to compare smile characteristics on a standard frontal on smiling view with selfie view of young adults.

**Material and Methods:** A cross-sectional pilot study was carried out at Islamabad dental hospital on 45 subjects, age ranging from 18 to 30 years. For each subject, a standardized frontal on smiling and selfie photograph was obtained and smile characteristics were analyzed by two trained professionals.

**Results:** The study showed both frontal on smiling view and selfie view had little difference when analysing smile characteristics such as smile arc, gingival display, incisor display and midline; however, there was a significant difference in reporting presence or absence of buccal corridors between the two views.

**Conclusions:** Selfie view may be used as an accessory photographic view to analyze smile characteristics. Buccal corridors showed a significant difference when viewed on frontal on smiling versus the selfie view.

**Keywords:** Soft tissue; smile; photographic analysis

## Introduction

Early orthodontic treatment was primarily based on occlusal relationship results.<sup>1</sup> A recent shift in paradigm from hard to soft tissue requires a harmonious balance between soft tissues and occlusion.<sup>2,3</sup> Soft tissue examination and analysis can be done clinically, radiographically or by photographic records.<sup>4,6</sup> Clinical photography has become an essential and indispensable tool in modern orthodontic practice.<sup>7</sup>

Smile has big psychological and social impact on an individual and has therefore become an important part of the soft tissue paradigm. A large percentage of people state that a non-pleasing smile is the main reason for seeking orthodontic treatment.<sup>8</sup>

A frontal on smiling photograph has been the

gold standard for analyzing smile aesthetics and individual characteristics in orthodontics. However with recent changes in photographic trends patients often make use of a selfie image to self-analyze their smile profile. A selfie, is a photograph: a pictorial image produced by a camera. According to oxford dictionary selfie is "A photograph that one has taken of oneself". With the growing selfie trend people are getting more and more conscious about their smile aesthetics and time and again use selfies as a mode of self-examination. Nearly 30% of photos taken by individuals between 18 and 24 in the UK are selfies.<sup>9</sup>

Dental professionals and laypersons often demonstrate a difference in perceptions of smile characteristics.<sup>10</sup> Patients and society predominantly focus on the final aesthetic outcome, which can be quite subjective to judge.<sup>11</sup> Therefore; several clinical and experimental studies have attempted to define how an aesthetically pleasing smile can be analysed.<sup>10-13</sup> These studies were, however, done on the same type of standardized frontal

<sup>a</sup> Corresponding Author. BDS; Resident, Department of Orthodontics, Islamabad Medical and Dental College, Islamabad. Email: amnah.munir@iideas.edu.pk

<sup>b</sup> BDS, MS; Professor/Head Department of Orthodontics, Islamabad Medical and Dental College, Islamabad.

<sup>c,d</sup> BDS; House officer; Islamabad Medical and Dental College, Islamabad.

on smiling images for both the professionals and the patients. Since most patients these days assess their treatment outcomes with a quick click of a selfie image, with the present study we aim to evaluate the differences between smile characteristics like smile arc, buccal corridors, gingival display, incisor display and dental midlines of frontal smiling and selfie photographs in young adults. The study provides us with new evidence on a concept with limited supportive evidence.

## Material and methods

A cross sectional pilot study was conducted on a sample of 45 subjects at Islamabad Dental Hospital, Islamabad. A trained professional clinically assessed and selected 45 young adults with pleasing smiles, in which characteristics like smile arc, dental midline, buccal corridor, gingival display, incisor display were ideal or according to the criteria (Table I). Written consent was obtained from subjects that were selected to undergo the study. A pair of frontal smiling and selfie view was taken for each participant.

**Table I: Inclusion and exclusion criteria**

Inclusion criteria	Exclusion criteria
Young adult subject with a pleasing frontal smile assessed clinically by trained observers	<ul style="list-style-type: none"> <li>• Occlusal canting</li> <li>• Gummy smile</li> <li>• Periodontally compromised dentition</li> <li>• Caries in anterior and posterior teeth disrupting the smile arc.</li> <li>• Restoration (filled, crown, bridge, implant) on anterior and posterior teeth disrupting the smile arc.</li> <li>• Staining/discolored teeth.</li> <li>• Attrition</li> <li>• Abrasion</li> <li>• Spacing/crowding</li> </ul>

Frontal photograph were with a DSLR camera in natural head position with the operator at a distance of 6 feet from the subject's face. Selfie view was taken by the subject himself/herself using a camera phone (iphone 6, 5MP without filter) at an arm's length distance with the camera placed in front. The orientation of the selfie view was predetermined by another pilot study carried out on a sample on 15 subjects. The subjects in small pilot were asked to take a selfie in the orientation they preferred the most. The most frequently used view for taking a selfie view; front facing at arm's length was chosen to be used in this study. Both photographs were cropped on a computer using 3x4 inch standard templates around the lip margin. The frontal and selfie views among patients were randomly shuffled and both the raters were blinded to it.

**Table II: description of smile characteristics**

Smile characteristics	
Smile arc	Consonant smile arc should follow the curvature of the lower lip line.
Dental midline	Should coincide with the center of the philtrum
Buccal corridor	Negative space lateral to the maxillary posterior teeth and the corner of the mouth.
Gingival display	Normal gingival display upto 2mm of gums visible on smiling
Incisor display	Full incisor show on smiling

Smile characteristics listed in Table II were clinically assessed and rated on a computer screen by two trained observers independently and rated on. Frontal on smiling view served as a control. Inter-rater reliability was calculated using the Cohen's kappa coefficient for each variable.

Data was analyzed using Pearson Chi-square test on SPSS software with confidence level at 95% and probability at 5%. Inter-rater

reliability was calculated for each variable using the Cohens kappa value.

### Results

Out of the 45 participants 20% were males and 80% were females with mean age of 22.8 years (Fig 1 and 2).

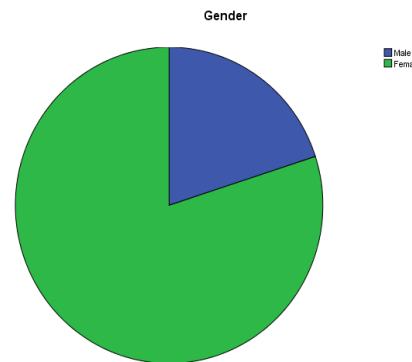
**Table III: Smile arc data distribution**

Smile arc					
Count		Average	Flat	Reverse	Total
Group	Selfie view	52	26	12	90
	Frontal smiling view	51	31	8	90
Total		103	57	20	
Pearson Chi-square Sig( 2-sided)		.536	Measurement of agreement Kappa Value		.782

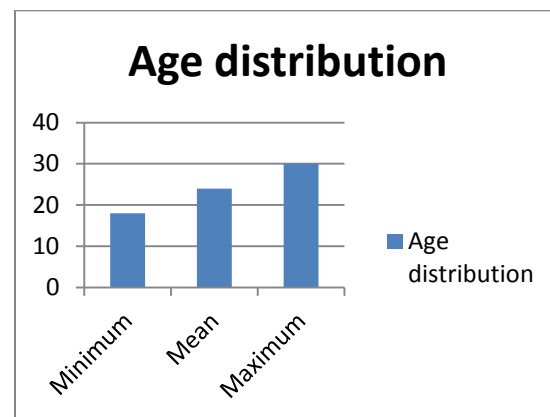
Both the raters showed a substantial amount of agreement when rating all the variables on frontal and selfie view. Although not statistically significant the smile arc on selfie view was rated 'reverse' for a greater number of subjects than that on frontal smiling view Table III.

There was no statistically significant difference for rating gingival display, incisor display and midlines for both frontal at smiling and selfie view, Table IV-VI

Buccal corridors showed a statistically significant difference when viewed on a frontal on smiling view in comparison to selfie view. The selfie view demonstrated presence of buccal corridors for 88% of the subject while frontal on smiling only showed presence of buccal corridors for 8.8% of the subjects, with both the raters showing a high level of agreement (Table VII).



**Figure 1: Gender distribution**



**Figure 2: Age Distribution**

**Table IV: Gingival display data distribution**

Gingival display					
Count		Adequate	Inadequate	Excessive	Total
Group	Selfie view	39	47	4	90
	Frontal smiling view	49	34	7	90
Total		88	81	11	180
Pearson Chi-square Sig( 2-sided)		.133	Measurement of agreement Kappa Value		.880

**Table V: Incisor Display data distribution**

Incisor display		Adequate	Inadequate	Excessive	Total
Group	Selfie view	78	8	4	90
	Frontal smiling view	77	6	7	90
Total		155	14	11	180
Pearson Chi-square Sig( 2-sided)	Chi-Sig( 2-sided)	.574	Measurement of agreement Kappa Value	.995	

**Table VI: Dental Midline data distribution**

Midline				
Count		Coincident	Non coincident	Total
Group	Selfie view	60	30	90
	Frontal smiling view	58	32	90
Total		118	62	180
Pearson Chi-square Sig( 2-sided)	.438	Measurement of agreement Kappa Value	.705	

**Table VII: Buccal corridors data distribution**

Count		Present	Absent	Total
Group	Selfie view	80	10	90
	Frontal smiling view	8	82	90
Total		88	92	180
Pearson Chi-square Sig( 2-sided)	0.00	Measurement of agreement Kappa Value		.911

## Discussion

Smile variable such as buccal corridors, smile arc, dental midlines, gingival margins and their effects on smile framework have been extensively discussed in literature. These characteristics have been analyzed

photographically on frontal smiling view by different panels or on computer software also using the classic frontal smiling view as the main tool.<sup>11-15</sup> Our results agree with literature in terms of frontal on smiling being an efficient tool for analyzing smile characteristics.

Literature demonstrates a difference in how dentists, orthodontists, and laypeople evaluate smiles. Orthodontists often perceive smile characteristics different from laymen and general dentists; this might be because most orthodontists receive a more formal training on smile esthetics. However, it does not indicate that the orthodontists' perceptions are more accurate than those of laypeople or dentists. It is more likely that orthodontists' perceptions have been skewed by their training. Orthodontists tend to follow a treatment philosophy and use subjective evaluation when treating patients. According to these studies orthodontists and layperson prefer smiles with small or no buccal corridors.<sup>11, 16</sup>

Frontal smiling photograph is taken in natural head position and has become a gold standard tool for smile analysis. The selfie can however be taken in different. Throughout history when posing for portraits people tend to offer their left cheek. This bias is also evident in selfies. Mechanical biases have been said to influence selfie posing orientation, as left hander people tend to favor taking selfies with the left cheek towards the camera. Selfies are almost always taken within an arm's length. People are more likely to take a front facing selfie (49.75%) than right (26.72%) than left (26.53%) cheek pose, regardless of sex, handedness, or hand used.<sup>17</sup> Based on these statistics and to standardize our methodology we chose to only include front facing selfies. We do however; believe that by changing the orientation different results may be obtained. Different selfie angulations, closeness, shallow depth, enhancement filters and odd cropping of selfies owe to a higher degree of

variance in picture quality.<sup>18</sup> These variations maybe a possible explanation for the difference in and smile characteristics, especially buccal corridors when compared with frontal smile view. Our results showed the presence of buccal corridors on selfie view in almost 80% of the cases compared to only 20% on frontal on smiling view which in our study served as a control for comparison. This disparity maybe due to the closeness of the camera to the subject, reduced camera quality and lack of flash component, all of which resulted in creating an image with more shadows. According to a recent study bad camera angles often lead to off-centered images and facial structures,<sup>19</sup> dental midline in our sample did however exhibit insignificant difference between the two views. This may be due to the fact that all the selfie views in our study were taken by the patients by placing the camera in a front facing angle.

Other variables like smile arc, gingival display and incisal display also demonstrated no differences between the two views which substantiate the reputation of the selfie view for analysing smile characteristics. The lack of significant difference between the two views for these variables may also be associated to the similar orientation of the selfie view and the frontal on smiling view. Had the orientation of the selfie view been changed to a more downward or upward direction, changes in the amount of gingival show may be different between the two views owing to a parallax error created by the camera angulation.

Based on this study's results we recommend further studies of the same nature to be carried out on a larger sample, using different selfie orientations as they may generate different results for these smile variables. These studies will allow the clinician to warn the patients of changes in smile characteristics based on their choice of selfie orientation. It is recommendation will be to incorporate the layperson's or the subject's view during

evaluation of the photographs for smile analysis as their observations maybe different from a trained professional.

This study reveals the use of frontal photograph on smiling view is essential for assessment of smile characteristics however considering the current changes in photographic trends there is need to consider selfie view for evaluating smile characteristics.<sup>20</sup>

## Conclusions

- Selfie view maybe used as an alternative tool in determining smile characteristics such as smile arc, gingival display, incisor display and dental midlines. This is however limited to only selfie view taken from the front of the subject at an arm length.
- Buccal corridors seem to be misreported a significant amount of times with the selfie view, with selfie view demonstrating darker buccal corridors for subjects reporting their absence on frontal on smiling view.
- Keeping in mind the changing trends and increased level of patient awareness, selfie view maybe considered as an accessory tool in leading to higher levels of patient satisfaction.
- Further studies should be carried out with different selfie angulations for determining facial and smile characteristics.

## References

1. Isiksal E, Hazar S, Akyalcin S. Smile esthetics: perception and comparison of treated and untreated smiles. *Am J Orthod Dentofacial Orthop.* 2006; 129:8-16.
2. Mcnamara L, mcnamara JA Jr, Ackerman MB, Baccetti T. Hard- and soft-tissue contributions to the esthetics of the posed smile in growing patients seeking orthodontic treatment. *Am J Orthod Dentofacial Orthop.* 2008; 133: 491-99.
3. David S, Interactions of hard tissues, soft tissues, and growth over time, and their impact on orthodontic diagnosis and treatment planning. *Am J Orthod Dentofacial Orthop* 2015; 148:380-6.

4. Oh J, Han JJ, Ryu SY, Oh HK, Kook MS, Jung S, Park HJ. Clinical and cephalometric analysis of facial **soft tissue**. *J Craniofac Surg*. 2017; 28(5):431-38
5. Fernández-Riveiro P, Suárez-Quintanilla D, Smyth-Chamosa E, Suárez-Cunqueiro M. Linear photogrammetric analysis of the soft tissue facial profile. *Am J Orthod Dentofacial Orthop*. 2002; 122(1):59-66.
6. Sarver DM, Ackerman MB. Dynamic smile visualization and quantification: part 2. Smile analysis and treatment strategies. *A J Orthod Dentofacial Orthop*. 2003; 124(2): 116-27.
7. Prabakaran R, Seymour S, Moles DR, Cunningham SJ. Motivation for **orthodontic treatment** investigated with Q-methodology: patients' and parents' perspectives. *Am J Orthod Dentofacial Orthop*. 2012; 142(2):213-20.
8. Hall M. Family Albums fade as the young put only themselves in the picture. *The Telegraph*. 2013. Available from: <http://www.telegraph.co.uk/technology/news/10123875/Family-albums-fade-as-the-young-put-only-themselves-in-picture.html> [ Accessed: 17-8-17]
9. Hiemstra R, Bos A, Hoogstraten J. Patients' and parents' expectations of orthodontic treatment. *J Orthod*. 2009; 36: 219-28.
10. Kokich, V., Kiyak, A.H., and Shapiro, P.A. Comparing the perception of dentists and laypeople to altered dental esthetics. *J Esthet Dent*. 1999; 11: 311-24.
11. Parekh SM, Fields HW, Beck M, Rosenstiel S. Attractiveness of variations in the smile arc and buccal corridor space as judged by orthodontists and laymen. *Angle Orthod*. 2006; 76:557-63.
12. Martin A, Buschang P, Boley J, Taylor R, McKinney T. The impact of buccal corridors on smile attractiveness. *Eur J Orthod*. 2007; 29:530-37.
13. Roden-Johnson D, Gallerano R, English J. The effects of buccal corridor spaces and arch form on smile esthetics. *Am J Orthod Dentofacial Orthop*. 2005; 127:343-50.
14. Jerrold L, Lowenstein LJ. The midline: diagnosis and treatment. *Am J Orthod Dentofacial Orthop*. 1990; 97: 453-62.
15. Sarver DM. The importance of incisor positioning in the esthetic smile: the smile arc. *Am J Orthod Dentofacial Orthop*. 2001; 120:98-111.
16. Zaib F, Hameed W. Effect of buccal corridors width on smile esthetics. *Pak Orthod J*. 2009;1(1):1-5.
17. Lindell AK. Motor biases do not influence posing orientation on selfies. *Laterality*. 2017; 22(1) 49-59. Available from: <http://dx.doi.org/10.1080/1357650X.2015.1109649> [Accessed: 17-08-17]
18. Frosh P. The gestural image: The selfie, photography theory, and kinesthetic sociability. *International Journal of Communication*. 2015; 9: 1607-28.
19. Saltz J. Art at Arm's Length: A History of the Selfie. *New York Magazine*. 2014. Available from: <http://www.vulture.com/2014/01/history-of-the-selfie.html> [Accessed: 17-08-17]
20. Sarver DM, *Orthodontics: current principles and techniques*, 6th edition. Elsevier; 2017.