

# Apical root resorption in Class II Div 1 malocclusion patients during en-masse maxillary anterior retraction with mini-screws

Uzma Lunia<sup>a</sup>, Norisha Ehsan Mahmood<sup>b</sup>, Ambreen Afzal Ehsan<sup>c</sup>, Hasnain Sakrani<sup>d</sup>

## Abstract

**Introduction:** Apical root resorption depends on a number of factors and orthodontic treatment is blamed to be one of them. Evaluation often requires radiographic measures and becomes paramount in certain cases. The objective of the present study was to determine the mean change in amount of apical root resorption in Class II Div 1 malocclusion patients treated with en-masse maxillary anterior retraction with the aid of mini-screws.

**Material and Methods:** This was a Quasi experimental study conducted at Department of Orthodontics, Altamash Institute of Dental Medicine, Karachi. A total of 40 patients with Angle class II Div I malocclusion were enrolled for this study and were aimed for treatment with fixed mechanotherapy (bonded brackets with Roth prescription). OPG was taken pre-treatment and after 6 months post bond-up. The amount of root resorption was measured with the help of vernier calipers. All information was noted on the proforma.

**Results:** Apical root resorption significantly increased after treatment ( $2.48 \pm 0.82$  vs  $1.66 \pm 0.46$ ; mean change =  $0.82 \pm 0.47$ ,  $p = 0.0005$ ).

**Conclusions:** Root resorption cannot be avoided with Orthodontic treatment. Measures must be taken to minimize it and patients with risk factors associated to root resorption must be identified prior to the start of fixed mechanotherapy. This phenomenon must be included in the consent form for every patient.

**Keywords:** Temporary Anchorage Devices; malocclusion; en-masse maxillary anterior retraction

## Introduction

Application of orthodontic forces to the teeth has unwanted side effects on the dentition. One of the common side effects is root resorption. External apical root resorption is an inflammatory process that leads to ischemic necrosis localized in the periodontal ligament when orthodontic force is applied resulting in permanent loss of tooth structure from the apex.<sup>1</sup> Multiple factors are involved in the mechanism including genetics, systemic factors, gender differences, type of tooth movements, magnitude,

duration and type of force.<sup>2-3</sup>

Anchorage control is fundamental to orthodontic treatment. Orthodontic mini-screws were developed as intraoral anchors for orthodontic tooth movement like incisor intrusion, canine retraction, en masse retraction of anterior teeth, distalization, molar up righting and protraction. They have no waiting time period, need of laboratory work, are easy to remove after treatment and have lower cost implications than prosthetic implants. Have advantages of being smaller sized and simpler placement.<sup>4-9</sup> With mini-screws teeth can be moved to a greater extent, positioned in ideal position and inclination, roots of teeth can travel farther and duration of treatment could be longer than conventional approaches, all of these contributing to root resorption.<sup>10-11</sup>

Radiographic examination of orthodontically treated patients showed some root resorption.

<sup>a</sup> BDS, FCPS-II Resident. Department of Orthodontics, Altamash Institute of Dental Medicine, Karachi

<sup>b</sup> BDS, Department of Orthodontics, Altamash Institute of Dental Medicine, Karachi

<sup>c</sup> Corresponding Author; BDS, FCPS, M.Orth RCS, Head Department of Orthodontics, Altamash Institute of Dental Medicine, Karachi. Email: drafzalehsan@gmail.com

<sup>d</sup> BDS,FCPS, Associate Professor, Department of Orthodontics, Altamash Institute of Dental Medicine, Karachi

The maxillary incisors have been regarded as the most susceptible teeth to root resorption. The external apical root resorption has not been studied thoroughly in patients with miniscrews.

The purpose of this prospective study was to evaluate the apical root resorption of maxillary incisors in orthodontic patients during en-masse retraction with mini screws. The reduction in root resorption is an aim during orthodontic treatment and may be controlled by reducing the risk factors. Susceptible patients may undergo periodic radiographs to detect severe root resorption and quickly reassess treatment goals.<sup>12</sup>

## Material and Methods

After getting approval from CPSP, the study was conducted on Orthodontic patients (both males and females) coming to the orthodontic department at Altamash Institute of Dental Medicine, between ages of 14-22 years. Patients were selected based on defined inclusion and exclusion criteria. All patients or guardians were informed about the purpose of study and informed consent was obtained from them. OPG was taken prior to treatment and a second radiograph was taken after 6 months. The amount of root resorption was measured with the help of vernier calipers. The measurement was done by the principle investigator and cross checked by the supervisor.

The statistical analysis was performed by using SPSS software package (SPSS Version 16.0). The mean and standard deviation was calculated for age, amount of apical root resorption before treatment and after treatment. Frequency and percentages were calculated for gender and teeth under consideration. Paired t-test was applied to compare the mean change in apical root resorption. Stratification with respect to age, gender, central and lateral incisors was done. Post stratification t-test was applied. P value of  $\leq 0.05$  was taken as significant.

## Results

A total of 40 patients with Angle Class II Div 1 malocclusion undertaking treatment with fixed bracket (Roth prescription) were selected for this study. The average age of the patients was  $18.2 \pm 2.36$  years (Figure 1). Out of 40 patients, 17 (42.5%) were males and 23 (57.5%) were females (Figure 2). Teeth considered were maxillary central incisors (42.5%) and maxillary lateral incisors (57.5%) as shown in Figure 3.

Pre and post mean change in amount of apical root resorption in Class II Div 1 malocclusion patients during en-masse maxillary anterior retraction with mini-screws was ascertained (Table I). Apical root resorption significantly increased after treatment as compare to pre op status ( $2.48 \pm 0.82$  vs.  $1.66 \pm 0.46$ ; mean change =  $0.82 \pm 0.47$ ;  $p = 0.0005$ ). Mean change in amount of apical root resorption also significantly increased after treatment as compared to before treatment in maxillary central incisors ( $p = 0.0005$ ) and lateral incisors ( $p = 0.0005$ ) (Table II). Similarly, stratification of age and gender was performed and observed the similar increment in mean amount of apical root resorption after the treatment (Table III and IV).

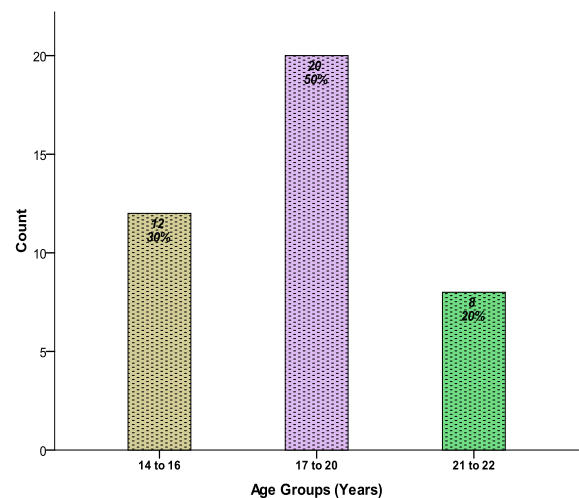


Figure 1. Age distribution of patients

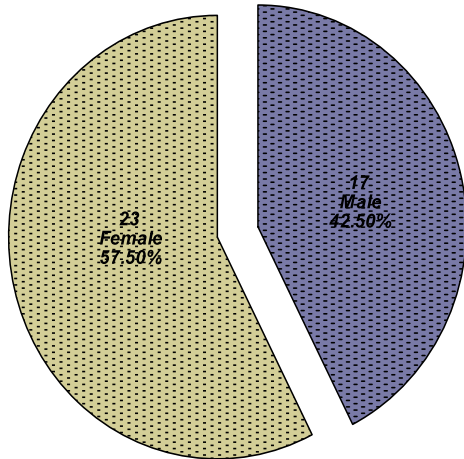


Figure 2. Gender distribution

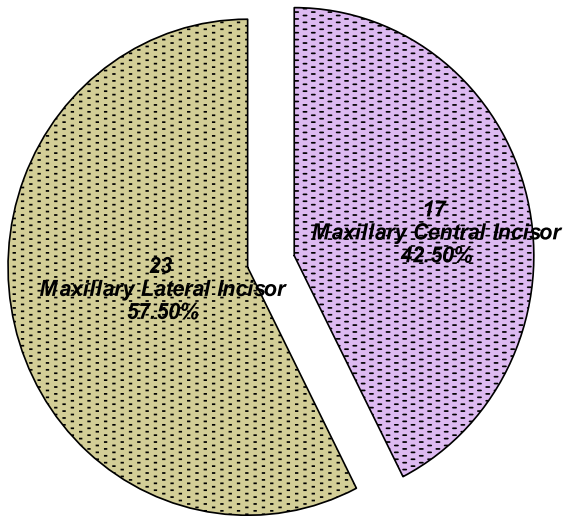


Figure 3. Frequency of Lateral and Central Incisors

Table I. Mean change in apical root resorption

Apical root Resorption	Pre operative	Post operative	(Post-pre) Changes	P-Value
Mean	1.66	2.48	0.82	0.0005
Standard deviation	0.46	0.54	0.47	

Table II. Mean change in amount of apical root resorption with respect to Maxillary central and lateral incisor

	Apical root Resorption			P-value
	Pre operative	Post operative	(Post-pre) Changes	
Maxillary Central Incisor (n=17)	1.80±0.61	2.41±0.46	0.61±0.42	0.0005
Maxillary Lateral Incisor (n=23)	1.56±0.47	2.55±0.46	0.98±0.45	0.0005

Table III. Age wise apical root resorption

Age Groups	Apical root Resorption			P-value
	Pre operative	Post operative	(Post-pre) Changes	
14 to 16 (n=12)	1.25±0.26	2.28±0.58	1.03±0.41	0.0005
17 to 20 (n=20)	1.66±0.52	2.52±0.42	0.85±0.47	0.0005
21 to 22 (n=8)	2.27±0.27	2.71±0.21	0.43±0.32	0.0005

Table IV. Gender wise Apical Root Resorption

Gender	Apical root Resorption			P-value
	Pre operative	Post operative	(Post-pre) Changes	
Male (n=17)	1.65±0.47	2.53±0.32	0.87±0.43	0.0005
Female (n=23)	1.67±0.59	2.45±0.54	0.78±0.51	0.0005

## Discussion

The growing demand for orthodontic treatment methods that require minimal compliance and maximal anchorage control, particularly by adults, has led to the expansion of implant technology.<sup>13</sup> Mini screws have been introduced as temporary anchorage devices for various purposes: canine retraction, anterior retraction, en-masse anterior retraction, molar up righting, distalization and protraction.<sup>13-18</sup> They have the advantages of being smaller sized, more implant placement sites, simpler placement methods, short or even no waiting period, no need for laboratory work, easier removal after treatment and lower cost than prosthetic implants and mini plates.

Without a limit to anchorage, teeth can be moved farther, to ideal positions and inclinations with mini screws. Nevertheless, the roots of maxillary or mandibular incisors would travel farther through the dento-alveolus and treatment could also be longer than with conventional approaches. All of these are considered predisposing factors for apical root resorption.<sup>19-20</sup>

In this study mean amount of apical root resorption was significantly increased after treatment as compared to before treatment ( $2.48 \pm 0.82$  vs.  $1.66 \pm 0.46$ ; mean change =  $0.82 + 0.47$ ;  $p = 0.0005$ ). Liou and Chang in their study showed that root resorption was  $2.6 + 1.25$  mm in patients treated with miniscrews for anterior maxillary en-masse retraction. Maxillary incisors of patients treated with mini-screw anchorage have been reported to be more vulnerable to apical root resorption than other teeth.<sup>21-22</sup>

The apical root resorption of the maxillary incisors after treatment was 2.5 to 2.8 mm, or 16.0% to 20.0% of their original root length; whereas before treatment it was 2.1 to 2.3 mm, or 13.4% to 14.4% of their original root length. Although the maxillary incisors were retracted farther in a longer time and apical root resorption of the maxillary lateral incisors was significantly more than that of

pretreatment group, their apical root resorption was still within the 3.0 mm reported previously for patients treated without mini screw anchorage.<sup>23-24</sup>

Mean change in amount of apical root resorption also significantly increased after treatment as compared to before treatment in maxillary central incisors ( $p = 0.0005$ ) and lateral incisors ( $p = 0.0005$ ) in the present investigation. Another study<sup>12</sup> ascertained apical root resorption of the maxillary lateral incisors to be greater than that of the maxillary central incisors in both genders and the apical root resorption of the maxillary lateral incisors in post treatment group was significantly more than in the pretreatment group. This could be because the appliances that were used for intrusion of the maxillary incisors were placed on the arch wire between maxillary canine and lateral incisor. Although the intrusive force was the same in the intrusion appliances, the force directed to the maxillary lateral incisors would be heavier than to the maxillary central incisors. The consequence could be greater apical root resorption in the maxillary lateral incisors than in the central incisors. Another explanation could be that the maxillary lateral incisors are inherently more vulnerable to apical root resorption than the maxillary central incisors.<sup>25-26</sup> There is some disagreement with this statement in the literature.<sup>27-28</sup>

It has been shown that the greater the tooth movement, more the apical root resorption.<sup>29-30</sup> Intrusive movements and forces are also thought to cause apical root resorption.<sup>31-32</sup> The severity of apical root resorption can be directly correlated to duration of treatment,<sup>33</sup> but there is disagreement on this hypothesis.<sup>34-35</sup> Conclusively, apical root resorption is multi factorial as discussed above.

Orthopantomogram radiographs can only detect apical root resorption after a certain amount of root shortening.<sup>36</sup> Furthermore; radiographs show only the phenomenon but

not the causes of apical root resorption. The underlying factors predisposing a patient to apical root resorption from orthodontic tooth movement are biologic rather than radiographic.<sup>37</sup> The factor of time could be a summation of all factors predisposing a patient to apical root resorption during orthodontic tooth movement.

## Conclusions

Mini screw anchorage allows for maxillary en-masse anterior retraction in patients with severe Class II malocclusion. Mechanics involving the use of mini-screws can be easily adopted in Orthodontic practice because of ease of application. The time needed for the greater amount of maxillary en-masse anterior retraction with mini screw anchorage is longer and might pre-dispose patients to more apical root resorption.

## References

- Anderson J O. Review of root resorption systems and models. Etiology of root resorption and the homeostatic mechanisms of the periodontal ligament. In: Davidovitch Z, editor. Biological mechanisms of tooth eruption and root resorption. Columbus, Ohio: The Ohio University; 1988. p. 9-22
- Brezniak N, Wasserstein A. Root resorption after orthodontic treatment: Part 1 Literature review. *Am J Orthod Dentofacial Orthop* 1993;62-6
- Brezniak N, Wasserstein A. Root resorption after orthodontic treatment: Part 2. Literature review. *Am J Orthod Dentofacial Orthop* 1993;103:138-46
- Brin I, Tulloch JFC, Koroluk L, Philips C. External apical root resorption in Class II malocclusion: a retrospective review of 1-versus 2-phase treatment. *Am J Orthod Dentofacial Orthop* 2003;124:151-6
- Brudvik P, Rygh P. The initial phase of orthodontic root resorption incident to local compression of the PDL. *Eur J Orthod* 1933; 15: 249
- Costa A, Raffaini M, Melsen B. Mini-screws as orthodontic anchorage: a preliminary report. *Int J Adult Orthod Orthognath Surg* 1998;13:201-9
- Costa A, Riffaini M, Melsen B. Mini-screws as orthodontic anchorage: a preliminary report. *Int J Orthod Orthognath Surg* 1998;13:201-9
- Deshield RW. A study of root resorption in treated Class II Division I malocclusion. *Angle Orthod* 1969;39:231-5
- Engstrom C, Granstom G, Thilander B. Effect of orthodontic force on periodontal tissue metabolism. *Am J Orthod Dentofacial Orthop* 1988;93:486-95
- Goldson L, Henirikson CO. Root resorption during Begg treatment: a longitudinal reontgenologic study. *Am J Orthod* 1975;68:55-66
- Hollender L, Ronnerman A, Thilander B. Root resorption, marginal bone support and clinical crown length in orthodontically treated patients. *Eur J Orthod* 1980; 2: 197-205
- Jimenez-Pellegrin C, Arana-Chavez VE. Root resorption repair in mandibular first premolars after rotation. A transmission electron microscopy analysis combined with immune-labeling of osteopontin. *Am J Orthod Dentofacial Orthop* 2007;132:230-6
- Kanomi R. Mini-implant for orthodontic anchorage. *J Clin Orthod* 1997;31:763-7
- Kanomi R. Mini-implant for orthodontic anchorage. *J Clin Orthod* 1997;31:763-7
- Lee A, Schneider G, Finkelstein M, Southard T. Root resorption: the possible role of extracellular matrix proteins. *Am J Orthod Dentofacial Orthop* 2004;126:173-7
- Lee JS, Park HS, Kyung HM. Micro-implant for lingual treatment of skeletal Class II malocclusion. *J Clin Orthod* 2001;35:643-7
- Lee JS, Park HS, Kyung HM. Micro-implant for lingual treatment of a skeletal Class II malocclusion. *J Clin Orthod* 2001;35:643-7
- Levander E, Malmgren O. Evaluation of the risk of root resorption during orthodontic treatment: a study of upper incisors. *Eur J Orthod* 1988;10:30-8
- Lin J C, Liou E J, Liaw J L. The survey and evaluation for the implant assisted orthodontics. *J Taiwan Orthod Assoc* 2001;13:14-21
- Lin JC, Liou EJ, Liaw JL. The survey and evaluation for the implant-assisted orthodontics. *J Taiwan Orthod Assoc* 2001;13:14-21
- Lin JC, Liou EJ. A new bone screw for orthodontic anchorage. *J Clin Orthod* 2003;37:676-81
- Lin JC, Liou EJ. A new bone screw for orthodontic anchorage. *J Clin Orthod* 2003;37:676-81
- Liou EJ, Chang PM. Apical root resorption in orthodontic patients with en-masse maxillary anterior retraction and intrusion with mini-screw. *Am J Orthod Dentofacial Orthop*. 2010;207-21213.
- Low E, Zoellner H, Kharbanda O P, Darendeliler M A. Expression of mRNA for osteoprotegerin and receptor activator of nuclear factor kappa b ligand (RANKL) during root resorption induced by the application of heavy orthodontic forces on rat molars. *Am J Orthod Dentofacial Orthop* 2005;128:497-503
- Malmgren O, Goldson L, Hill C, Orwin A, Petrini L, Lundberg M. Root resorption after orthodontic

- treatment of traumatized teeth. *Am J Orthod* 1982;82:487-91
26. McFadden W M, Engstrom C, Engstrom H, Anholm J M. A study of the relationship between incisor intrusion and root shortening. *Am J Orthod Dentofacial Orthop* 1989;96:390-6
  27. Park HS, Bae SM, Kyung HM, Sung JH. Micro-implant anchorage for treatment of skeletal Class I bi-alveolar protrusion. *J Clin Orthod* 2001;35:417-22
  28. Park HS, Bae SM, Kyung HM. Micro-implant anchorage for treatment of skeletal Class I bi-alveolar protrusion. *J Clin Orthod* 2001;35:417-22
  29. Reitan K. Effects of force magnitude and direction of tooth movement on different alveolar bone types. *Angle Orthod* 1964;34:244-55
  30. Reitan K. Initial tissue behavior during apical root resorption. *Angle Orthod* 1974; 44:68-82
  31. Reitan K. Initial tissue behavior during apical root resorption. *Angle Orthod* 1974;44:68-82
  32. Remington D N, Joondeph D R, Artun J, Riedel R A, Chapko M K. Long-term evaluation of root resorption occurring during orthodontic treatment. *Am J Orthod Dentofacial Orthop* 1989;96:43-6
  33. Rosenberg HN. An evaluation of the incidence and amount of apical root resorption and dilaceration occurring in orthodontically treated teeth, having incompletely formed roots at the beginning of Begg treatment. *Am J Orthod* 1972;61:524-5
  34. Rygh P. Orthodontic root resorption studied by electron microscopy. *Angle Orthod* 1977;47:1-16
  35. Rygh P. Ultrastructural changes in tension zones of rat molar periodontium incident to orthodontic tooth movement. *Am J Orthod* 1974;70:269-81
  36. Shafer W G, Hine M K, Levi B M. A textbook of oral pathology. 4th ed. Philadelphia: W.B. Saunders; 1983. p. 328-32
  37. Sjolien T, Zachrisson B U. Periodontal bone support and tooth length in orthodontically treated and untreated persons. *Am J Orthod* 1973;64:28-37
  38. Smale I, Artun J, Behbehani F, Doppel D, vant Hof M, Kuijpers - Jagtman A M. Apical root resorption 6 months after initiation of fixed orthodontic appliance therapy. *Am J Orthod Dentofacial Orthop* 2005;128:57-67
  39. Tronstad L. Root resorption – a multidisciplinary problem in dentistry. In: Davidovitch Z, editor. Biological mechanisms of tooth eruption and root resorption. Columbus, Ohio: The Ohio University; 1988. p. 293-302