

# Frequency of dental anomalies in patients with impacted maxillary canine

Ali Ayub<sup>a</sup>, Shahzad Ali Khalil<sup>b</sup>, Sidra Aamer<sup>c</sup>

## Abstract

**Introduction:** Patients reporting for Orthodontic treatment have various treatment needs ranging from simple to complex problems. Impacted canines pose a challenge to Orthodontists that is mostly associated with other anomalies as well. Hence the purpose of this study was to determine the frequency of dental anomalies in patients with impacted canines in a sample of Pakistani population.

**Material and Methods:** Fifty patients having impacted canine diagnosed on orthopantomogram were included in this study. The dental anomalies like agenesis, other tooth impaction, morphological variations, supernumerary teeth and transpositions were ascertained. The data was analyzed using SPSS version 20.0.

**Results:** Out of total 50 patients having impacted canines, 29(58%) were females and 21(42%) were males. 70% impactions were palatal and 30% were buccal. Only 10% of had bilateral impactions. 50% patients with impacted canines had associated dental anomalies. The most common anomaly was peg shaped lateral incisor (20%) followed by impacted premolars (8%). Sexual dimorphism did not exist in the present sample.

**Conclusions:** Fifty percent of patients having impacted maxillary canines had associated dental anomalies.

**Keywords:** Peg shaped lateral incisors; impacted premolar; tooth agenesis

## Introduction

Maxillary canine of all the teeth has the longest path and deepest path of development and the most devious course to travel from its point of origin to full eruption into occlusion.<sup>1</sup> Hence it is of interest to dentists from a developmental point of view. The maxillary canine is the second most common tooth affected by impaction after the third molars with a prevalence of 1%–3%.<sup>2</sup> It is twice as common in females as it is in males.<sup>3</sup> The incidence of canine impaction in

the maxilla is more than twice than that in the mandible. Of all the patients who have impacted maxillary canines, 8% have bilateral impactions.<sup>4</sup> Approximately one-third of impacted maxillary canines are located labially and two-thirds are located palatally.<sup>5</sup> Although some researchers are in favor of an exclusively genetic etiology for its occurrence, it is believed to be multi factorial.<sup>6</sup> The causes can be classified into 4 distinct groups namely local hard tissue obstruction, local pathology, disturbance of the normal development of incisors and hereditary or genetic factors.<sup>7</sup>

Early detection of this pathology is therefore fundamentally important. Only this can ensure successful preventive measures. However, the ectopic location and / or impaction of a maxillary canine might not be easy to predict early or diagnose. It's difficult to localize impacted canines precisely and the position invariably affects treatment

<sup>a</sup> Corresponding Author: BDS, FCPS. Assistant Professor, Department of Orthodontics, Foundation University College of Dentistry, Islamabad, Pakistan. Email: aliyub078y@gmail.com

<sup>b</sup> BDS. Dental Surgeon, Rehman Medical Institute, Peshawar, Pakistan.

<sup>c</sup> BDS, MSc. Associate Professor, Department of Dental Materials, Foundation University College of Dentistry, Islamabad, Pakistan.

strategies and protocols for prevention of this impaction.

In recent years, the introduction of computerized tomography has contributed to a more exact location of ectopic teeth.<sup>8</sup> In spite of such advances reliable diagnostic criteria for the prediction and prevention of this condition have yet to be definitively defined. Thus, it has become important to identify early-risk indicators that can aid in predicting impaction of permanent maxillary canines.<sup>9</sup> Studies have been carried out regarding the association of Palatally displaced canines (PDC) with congenitally missing teeth<sup>10,11</sup>, in particular, associations with maxillary lateral incisors<sup>12</sup> and second premolar aplasia<sup>13</sup> have been observed. Numerous studies have highlighted the association between PDC and tooth size reduction, especially of the maxillary lateral incisor.<sup>10,12</sup> Also, the transposition of maxillary canine to first premolar and maxillary lateral incisor to canine have been associated with PDCs.<sup>14,15</sup>

As ethnic, genetic and environmental factor affect prevalence and association of dental anomalies in impacted canine cases, so the objective of this study was to determine the frequency and association of dental anomalies in patients with impacted maxillary canines in a Pakistani (Peshawar) population.

## Material and Methods

This retrospective study was conducted at the department of Orthodontics, Khyber College of Dentistry, Peshawar using existing records of Orthodontic Patients. The sample comprised of 50 patients with impacted maxillary canines. Patients of Pakistani origin having impacted maxillary canines (between 12 to 25 years) were included in the sample. Patients with oro-facial clefts, medical complications including metabolic and endocrine disorders and those with incomplete or poor quality records were excluded from the sample.

The radiographs were examined in a darkened room using an illuminated x-ray viewing box, and the impaction of the canine

was confirmed. The position of the impacted canine was determined using standardized vertical parallax radiographic techniques using OPG and occlusal x-rays. Radiographs along with intra-oral photographs and study casts were also used to confirm the presence of other dental anomalies. The dental anomalies evaluated were agenesis of teeth (excluding the maxillary and mandibular third molars, impaction of other teeth (excluding the maxillary and mandibular third molars), peg-shaped maxillary lateral incisors, supernumerary teeth and transpositions.

The data was analyzed using SPSS version 20.0. Frequencies were calculated for dental anomalies in buccal and palatal impacted maxillary canine cases. Stratification was done for dental anomalies by type of maxillary canine impaction (buccal and palatal) and gender using chi-square test.  $P < 0.05$  was considered to be significant.

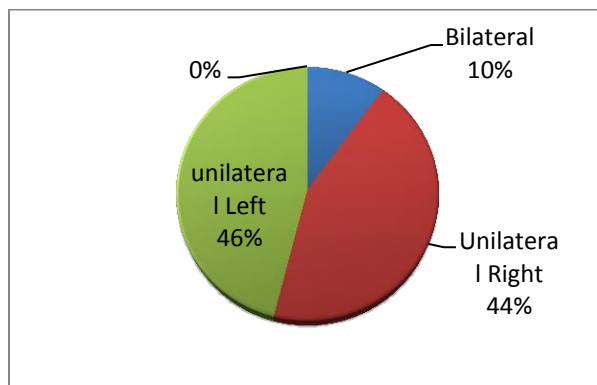
## Results

Out of total 50 patients having maxillary impacted canines, 29 (58%) were females and 21 (42%) were males. Of these 50 patients, 36 (70%) were palatal and 14 (30%) were buccal. Only 10% of cases had bilateral impaction (Fig 1). Twenty-five (50%) patients with impacted canines had dental anomalies as shown (Table I). The most common anomaly was peg shaped lateral incisor (20%) followed by impacted premolar (8%). Congenital missing mandibular premolars and transposition were 4%. 6% of the cases had missing maxillary lateral incisor. None of the dental anomalies in this sample had statistically significant difference between males and females (Table II).

**Table I: Prevalence of dental anomalies in maxillary impacted canine cases (n=50)**

DENTAL ANOMALIES	FREQUENCY	PERCENTAGES
Peg lateral incisor	10	20
Missing lateral incisor	3	6.0
Transposition	2	4.0

Congenitally missing mandibular incisor	1	2.0
Congenitally missing mandibular premolar	2	4.0
Supernumerary	1	2.0
Impacted premolar	4	8.0
Impacted molar	1	2.0
<b>Total</b>	<b>24</b>	<b>48</b>



**Figure 1: Distribution of maxillary canine impaction on basis of side**

**Table II: Prevalence of dental anomalies in impacted canine cases (n=25)**

DENTAL ANOMALIES	Frequency		Percentages		$\chi^2$	p-value*
	Male	Female	Male	Female		
Peg lateral incisor	4	6	8.0	12.0	1.4655	0.4935
Missing lateral incisor	1	2	2.0	4.0	1.5308	0.432
Transposition	0	2	0.0	4.0	3.191	0.173
Congenitally missing mandibular incisor	1	0	2.0	0.0	2.203	0.177
Congenitally missing mandibular premolar	0	2	0.0	4.0	3.191	0.173
Supernumerary	1	1	2.0	2.0	1.394	0.396
Impacted premolar	2	2	4.0	4.0	1.513	1.513
Impacted molar	0	1	0.0	2.0	2.220	0.267
<b>Total</b>	<b>9</b>	<b>16</b>	<b>16</b>	<b>32</b>		

\*chi-square test at  $p < 0.05$  significant level

## Discussion

During the odontogenesis process any disturbance can lead to dental anomalies. It

can results in disturbance of size, number, shape, structure and position of teeth. These are rare occurrences, but can be very challenging to diagnose and manage. The nature, type and severity can vary with ethnicity and geography. It is of paramount importance to know the prevalence of these anomalies for better care of patients in our population.<sup>16</sup>

In the present study, females (58%) were more in number than males (42%). The high percentages of females in this study may be due to the high esthetic concern among them when compared with males. Malnutrition, lifestyle, habits, Drug abuse and other environmental factors can also play a role for having such problems. Loh HS et al<sup>17</sup> conducted a study on Coronal morphology of the mandibular second premolar in the Singaporean Chinese population but had a greater incidence of canine impaction in the male part of their sample. Altug-Atac AT et al<sup>18</sup> conducted a study on Turkish population on prevalence of dental anomalies in orthodontic patients and included a sample of 1658 girls and 1385 boys. Their sample also had more females as compared to males. Contrary to the present study this was a large sample.

70% of the patients had palatal whereas 30% had buccal impactions. Sukhia HR et al<sup>18</sup> reported similar result about 67% palatal impaction. Patil S et al<sup>20</sup> determined the prevalence of impacted canines in the population of western part of India. They reported that most of the impactions constituted palatally placed canines (88.6%, 108 canines) and only 11.4% (14 canines) were located buccally. These finds corroborate with the present study. In the present study out of 50 (20%), twenty patients had bilateral impactions whereas 80% had unilateral impactions.

Bishara S E<sup>21</sup> reported prevalence of bilaterally impacted canines to be 8%. Patil S et al<sup>20</sup> reported the same phenomenon focusing Western part of India and concluded

that about 94% of cases had unilateral impacted canines. This can be owed to smaller sample of the current study, ethnic and genetic variability.

In the current study, about 50% of the patients had dental anomalies. Sajnani A K et al<sup>9</sup> determined the association of both buccal and palatally impacted canines with other dental anomalies a population of 533 Southern Chinese children and adolescents. They reported that 47% had dental anomalies. These results are similar to the present study. The most common anomaly was peg shaped lateral incisor (20%) followed by impacted premolar (8%). Congenital missing mandibular premolars and transposition were 4%. Six percent of the cases had missing maxillary lateral incisor. Similar results were reported by Sajnani AK et al.<sup>9</sup> A study by Jena AK<sup>22</sup> on Indian population reported that about 38% patients with impacted maxillary canines had peg shaped lateral incisors. The difference in results may be due to genetic and ethnic variation. Similar to our study, Mercuri E et al<sup>2</sup> reported about 24% of peg shaped lateral incisors in their sample with impacted canines. Other studies reported the prevalence of small or peg-shaped lateral incisors to be between 16% and 18%.<sup>23,24</sup> Brin I et al<sup>25</sup> reported that cases having impacted canines had about 42% combined missing and peg shaped lateral incisor while in the present study only 26% of cases had missing and peg shaped lateral incisors. The difference may be due to a smaller sample size and ethnic and genetic variation.

## Conclusions

Fifty percent of patients having impacted maxillary canines had associated dental anomalies. This can alarm the treating Orthodontist of the possibility of complex treatment with involvement of various specialists in order to provide optimal treatment to the patient

## References

1. Nagpal A, Pai KM, Sharma G. Palatal and labially impacted maxillary canine-associated dental

- anomalies: a comparative study. *J Contemp Dent Pract* 2009 Jul 1;10(4):67-74
2. Mercuri E, Cassetta M, Cavallini C, Vicari D, Leonardi R, Barbato E. Dental anomalies and clinical features in patients with maxillary canine impaction: a retrospective study. *Angle Orthod* 2012;83(1):22-8
3. Manne R, Gandikota C, Juvvadi S R, Rama H R, Anche S. Impacted canines: etiology, diagnosis, and orthodontic management. *J Pharm Bioall Sci* 2012;4(6):234
4. Iltis G. A review of early displaced maxillary canines: Etiology, diagnosis and interceptive treatment. *Open Dent J* 2011;5:39-47
5. Ericson S, Kurol J. Early treatment of palatally erupting maxillary canines by extraction of the primary canines. *Eur J Orthod* 1988;10:283-95
6. Johnston WD. Treatment of palatally impacted canine teeth. *Am J Orthod* 1969;56:589-96.
7. Becker A, Chaushu S. Etiology of maxillary canine impaction: A review. *Am J Orthod Dentofacial Orthop* 2015;148(4):557-67
8. Walker L, Enciso R, Mah J. Three dimensional localization of maxillary canines with cone-beam computed tomography. *Am J Orthod Dentofacial Orthop* 2005;128:418-23
9. Sajnani AK, King N M. Dental anomalies associated with buccally and palatally-impacted maxillary canines. *J Investigat Clin Denti* 2014;5(3):208-13
10. Peck S, Peck L, Kataja M. The palatally displaced canine as a dental anomaly of genetic origin. *Angle Orthod* 1994;64: 249-56
11. Peck S, Peck L, Kataia M. Prevalence of tooth agenesis and peg-shaped maxillary lateral incisor associated with palatally displaced canine (PDC) anomaly. *Am J Orthod Dentofacial Orthop* 1996;110:441-3
12. Leifert S, Jonas I. Dental anomalies as a micro symptom of palatal canine displacement. *J Orofac Orthop* 2003;64:108-20
13. Baccetti T. A controlled study of associated dental anomalies. *Angle Orthod* 1998;68: 267-74
14. Camilleri S. Maxillary canine anomalies and tooth agenesis. *Eur J Orthod* 2005; 27(5):450-6
15. Peck S, Peck L, Attia Y. Mandibular lateral incisor-canine transposition, concomitant dental anomalies and genetic control. *Angle Orthod* 1998;68:455-66
16. Khan S Q, Ashraf B, Khan N Q, Hussain B. Prevalence of dental anomalies among orthodontic patients. *Pak Oral Dent J* 2015;35(2):224-7
17. Loh H S. Coronal morphology of the mandibular second premolar in the Singaporean Chinese. *Aust dent J* 1991;38(4):283-6
18. Altug-Atac A T, Erdem D. Prevalence and distribution of dental anomalies in orthodontic patients. *Am J Orthod Dentofacial Orthop* 2007;131(4):510-4

19. Sukhia H R, Sukhia R H, Baloch D A, Iqbal Z. Impacted Canines in Orthodontic Patients at Jinnah Medical and Dental College. A Cross Sectional Study. *J Pak Dent Assoc* 2011; 20(2):73-6
20. Patil S, Maheshwari S, Santosh B S, Khandelwal S. Prevalence of impacted canines in population of western part of India. *Univ Res J Dent* 2014;4:148-52
21. Bishara SE. Impacted maxillary canines: A review. *Am J Orthod Dentofacial Orthop* 1992;101:159-71
22. Jena A K, Duggal R. The pattern of maxillary canine impaction in relation to anomalous lateral incisors. *J Clin Pediat Dent* 2010;35(1):37-40
23. Basdra E K, Kiokpasoglou M, Stellzig A. The Class II division 2 craniofacial type is associated with numerous congenital tooth anomalies. *Eur J Orthod* 2000;22:529-35
24. Basdra E K, Kiokpasoglou M, Komposch G. Congenital tooth anomalies and malocclusion. A genetic link? *Eur J Orthod* 2001;23:145-51
25. Brin I, Becker A, Shalhav M. Position of the maxillary permanent canine in relation to anomalous or missing lateral incisors: a population study. *Eur J Orthod* 198 ;8(1):12-6